

Vascular Endothelial Growth Factor Antagonist Therapy for Retinopathy of Prematurity



M. Elizabeth Hartnett, MD

KEYWORDS

- Vascular endothelial growth factor • Physiologic retinal vascular development (PRVD)
- Intravitreal neovascularization (IVNV) • Bevacizumab • Angiogenesis
- Oxygen-induced retinopathy (OIR)

KEY POINTS

- Before considering anti-vascular endothelial growth factor (VEGF) agents in preterm infants, more studies are needed to determine long-term effects on safety, proper doses, or even the type of anti-VEGF agent or other drug.
- Retinopathy of prematurity phenotypes may vary throughout the world based on environmental factors and potential differences in genetic variants. These considerations are important when comparing outcomes from clinical reports after anti-VEGF therapy.
- Although there is promise with anti-VEGF treatment, there is clinical risk of poor outcome and safety concerns potentially from systemic reduction of VEGF. Other treatments are needed.

INTRODUCTION

Over the past several decades, vascular endothelial growth factor (VEGF) has become recognized as an important pathologic angiogenic factor in several eye diseases, including age-related macular degeneration (AMD),^{1–3} diabetic retinopathy,^{4,5} retinal vein occlusion,⁴ and retinopathy of prematurity (ROP). Before US Food and Drug Administration (FDA) approval of anti-VEGF agents for AMD, a disease affecting elderly adults, preclinical studies tested VEGF inhibitors in animal models of angiogenesis, including models of oxygen-induced retinopathy (OIR) in which blood vessels grow into the vitreous cavity similar to what occurs in diabetic retinopathy and ROP.^{6,7} After proven efficacy that anti-VEGF agents reduced intravitreal angiogenesis

Disclosure: NIH grants: NEI R01EY017011, NEI R01EY015130. March of Dimes grant: FY-13-75. Department of Ophthalmology and Visual Sciences, John A. Moran Eye Center, University of Utah, 65 Mario Capecchi Drive, Salt Lake City, UT 84108, USA
E-mail address: me.hartnett@hsc.utah.edu

Clin Perinatol 41 (2014) 925–943
<http://dx.doi.org/10.1016/j.clp.2014.08.011>

perinatology.theclinics.com

0095-5108/14\$ – see front matter © 2014 Elsevier Inc. All rights reserved.

in preclinical testing in models of OIR and aberrant angiogenesis in clinical trials for neovascular AMD and adult eye diseases, a clinical trial was performed to test the effect of inhibiting the bioactivity of VEGF using the monoclonal antibody, bevacizumab, in severe ROP.⁸ Success was reported in a subgroup of preterm infants with zone I, stage 3 ROP with plus disease. However, concerns remain.

No dosing studies were performed to determine an effective and safe dose or optimal agent for ROP. VEGF is an important angiogenic factor in development, a survival factor of newly formed capillaries, and also plays a role in the homeostasis of already developed vasculature.^{9,10} In adults, repeated treatment with anti-VEGF agents, the standard of care for AMD, has been associated with geographic atrophy, another cause of vision loss in AMD.¹¹ VEGF is also a neuroprotective agent for retinal neurons.¹² Therefore, concerns of damaging effects from anti-VEGF were raised, particularly in the developing infant retina. In addition, anti-VEGF agents injected into the vitreous cavity reduced serum VEGF for several weeks,^{13,14} raising additional concern of the effects of removing systemic VEGF on the development of organs, particularly kidney, brain, and lung in the preterm infant. Following the publication of the clinical trial, complications were reported after a single intravitreal injection of bevacizumab. These complications included persistent avascular retina, recurrent intravitreal angiogenesis, and stage 5 retinal detachment.^{15,16} Therefore, before considering anti-VEGF agents in preterm infants, more studies are needed to determine long-term effects on safety, proper doses, or even the type of anti-VEGF agent or other drug.

In this article, the growing problem of ROP worldwide, the standard of care laser treatment in severe ROP, and the need for new treatments are discussed. Also discussed are the reasons to consider inhibiting the VEGF signaling pathway in ROP and the concerns about broad inhibition. Finally, the potential role of VEGF in ROP based on studies in OIR models, the effects of anti-VEGF based on basic research data, and the clinical relevance of these data are covered.

THE PROBLEM: RETINOPATHY OF PREMATURITY IS INCREASING WORLDWIDE AND HAS DIFFERENT PHENOTYPES

With increases in preterm births, ROP has become one of the leading causes of childhood blindness worldwide.¹⁷ In the United States, ~14% of childhood blindness is attributed to ROP and in some developing nations estimates are greater than 20%.¹⁸ In addition, some countries have developed the ability to save preterm infants but lack resources to regulate oxygen and are experiencing not only cases of ROP from extreme prematurity but also additional cases of ROP in larger and older infants from high oxygen-induced damage to newly formed retinal capillaries similar to what occurred in the 1940s and 1950s in the United States, United Kingdom, and Canada.^{15,19,20} Compounding these increases in ROP cases throughout the world, the number of adequately trained ophthalmologists to diagnose and treat ROP is not increasing to meet the need.¹⁹ There also appears to be a heritable component to ROP,²⁰ and genetic pools differ throughout the world. Thus, ROP phenotypes may vary throughout the world based on environmental factors and, potentially, differences in genetic variants. These considerations are important when comparing outcomes from clinical reports after anti-VEGF therapy.

CURRENT TREATMENT FOR RETINOPATHY OF PREMATURITY AND REASONS FOR BETTER THERAPIES

When ROP was first diagnosed as retrolental fibroplasia in the 1940s in the United States, studies in animal models were performed that revealed that high oxygen at

birth was a cause.²¹ Oxygen damaged newly formed retinal capillaries and led to broad areas of avascular retina.^{21,22} When the infant was moved from high oxygen to a relatively hypoxic environment, cells within the avascular retina were stimulated by hypoxia and thought to increase the expression of angiogenic growth factors.²³ Now several mechanisms are proposed, including the stabilization and nuclear translocation of hypoxia-inducible factors that cause transcription of angiogenic factors, including VEGF.²⁴ However, rather than vascular growth into the avascular retina to relieve the hypoxic stimulus, vessels grow into the vitreous. Efforts were made to reduce oxygen, which drastically reduced cases of ROP but also increased infant morbidity and mortality. With advances in neonatal care and the ability to regulate oxygen, ROP re-emerged as smaller and younger preterm infants were surviving.

In the 1990s, the Supplemental Therapeutic Oxygen for Prethreshold ROP multicenter trial tested the hypothesis that increased supplemental oxygen treatment would reduce the hypoxic stimulus for vasoproliferation and thereby prevent severe ROP (Table 1). However, only in a post-hoc analysis was reduced progression to severe ROP noted in a subgroup with higher oxygen saturation (94%–99% SaO₂) compared with conventional oxygen saturation (89%–94% SaO₂).²⁵ Other smaller studies reported that supplemental oxygen later in the neonatal course in the nursery reduced severe ROP.^{25,26} More recent studies tested the hypotheses that lower than conventional oxygen saturation targets would reduce severe ROP.^{27–29} In 2 studies, the Surfactant, Positive Airway Pressure, Pulse Oximetry Randomized Trial³⁰ and Benefits of Oxygen Saturation Targeting,³⁰ low oxygen saturation targets were associated with lower incidence of ROP but higher mortality, whereas in the Canadian Oxygen Trial,²⁹ there was no effect on ROP or mortality.³⁰ However, the studies had important differences, including potentially regional differences in the phenotype of ROP of enrolled infants (see Table 1).³¹ The conclusion from these studies is that even when oxygen is regulated, ROP can still occur in the smallest and youngest preterm infants.

Fluctuations in oxygenation have also been associated with severe ROP.³² There is speculation that strict control of oxygen levels may lead to more fluctuations in oxygenation in preterm infants because of the difficulty in maintaining oxygen saturation levels within a tight range.³³ Repeated fluctuations in oxygen delivery in animal models leads to increased oxidative compounds,³⁴ overexpression of VEGF and VEGF receptor 2 (VEGFR2), and also overactivation of signaling cascades involving VEGFR2.^{3,35} Besides fluctuations in oxygenation, risks for human ROP have included associations with poor infant growth³⁶ and increased oxidative stress.^{37–39}

The current standard of care for ROP of all causes is treatment of the peripheral avascular retina with laser, preferably to cryotherapy, when a level of severity (type 1 ROP) develops (Tables 2 and 3).⁴⁰ There are several considerations for successful treatment. First, timing of treatment is critical. Early treatment of type 1 ROP before threshold ROP⁴⁰ occurs led to the prevention of blindness in more than 90% of enrolled infants whereas about a 75% success rate was reported in the multicenter study, Cryotherapy for ROP (see Table 2; Table 4).⁴¹ Eyes that advance in severity of ROP beyond threshold do not respond well to laser, cryotherapy, or surgery.⁴² Diagnosis and treatment with laser or cryotherapy require skill using an indirect ophthalmoscope and a scleral depressor.⁴³ Although wide-angle retinal imaging is being used as an aid in diagnosis,⁴⁴ treatment with laser or cryotherapy still requires ability with an indirect ophthalmoscope to target the appropriate areas in the retina. Subsequently, it is essential to have adequately trained ophthalmologists and staff who can diagnose⁴⁵ and treat severe ROP. Unfortunately, there is a shortage of suitably trained ophthalmologists who are willing to diagnose and treat preterm infants for ROP.^{17,44} Adequate treatment and ability to determine when re-treatment is needed

Table 1
List of major oxygen trials

Trial	Dates	Enrolled	Exclusion	% Not Meeting Inclusion Criteria	Geography	Birth Weight (Mean or Range)	Intervention	Outcome	Mortality
STOP-ROP	1994–1999	30–48 wk GA with prethreshold ROP in one eye and median Sao ₂ <94%	Median Sao ₂ >94% or congenital abnormality	34%	US	726 g	Infants randomized to Sao ₂ ranges of 89%–94% or 96%–99%	No significant difference in threshold ROP. In subgroup, threshold ROP < infants without Plus disease in 96%–99% Sao ₂ group	Not assessed formally, 7 infants in lower oxygen tension group vs 9 infants in the higher tension group died
SUPPORT	2005–2009	24–27 wk GA 6 d at birth who underwent full resuscitation	Infants with major congenital abnormalities	6.6%	US	825–836 g	1. Randomized to early CPAP or early surfactant 2. Randomized to Sao ₂ of 85%–89% or 91%–95%	Decreased ROP in 85%–89% Sao ₂ group	Increased mortality in 85%–89% Sao ₂ group

BOOST II	2006–2011	<28 wk GA	<ol style="list-style-type: none"> 1. Unlikely to survive 2. Major congenital abnormality 3. Unavailable for follow-up 	9%	Australia, UK, New Zealand	826-837 g	Randomized to Sao ₂ of 85%–89% or 91%–95%	Decreased ROP in 85%–89% Sao ₂ group	Increased mortality when targeting Sao ₂ <90%
COT	2006–2012	>23 wk–27 wk and 6 d GA	<ol style="list-style-type: none"> 1. Not viable 2. Persistent pulmonary hypertension 3. Dysmorphic features or congenital malformations 4. Cyanotic heart disease 5. Unavailable for follow-up 	16%	Canada, US, Argentina, Finland, Germany, Israel	827-845 g	Randomized to Sao ₂ of 85%–89% or 91%–95%	No significant difference between Sao ₂ targets on ROP at 18 mo	No significant difference between Sao ₂ targets on death or disability at 18 mo

Abbreviations: BOOST, Benefits of Oxygen Saturation Targeting; COT, Canadian Oxygen Trial; GA, gestational age; Sao₂, oxygen saturation; STOP-ROP, Supplemental Therapeutic Oxygen for Prethreshold Retinopathy of Prematurity; SUPPORT, Surfactant, Positive Airway Pressure, Pulse Oximetry Randomized Trial.

Table 2	
Prethreshold and threshold ROP	
Type 1 ROP, (high-risk) prethreshold ROP	
Zone I	Any stage with plus disease
Zone I, stage 3	Without plus disease
Zone II, stage 2 or 3	With plus disease
Type 2 ROP, (low risk) prethreshold ROP	
Zone I, stage 1 or 2	Without plus disease
Zone II, stage 3	Without plus disease

are important, and only a few studies have addressed the factors associated with progression of retinal detachment following laser treatment and the window of surgical opportunity.^{46,47} Finally, laser treatment for severe ROP may take 2 or more hours to perform, whereas the time to perform an intravitreal injection is often less than 30 minutes. This shorter length of treatment time adds an incentive to find methods of treatment besides laser for ROP. However, adequate research and testing for safety and efficacy are needed.

TOWARD A TREATMENT SOLUTION

It is important to review new evidence regarding the pathophysiology of ROP that has been realized since early studies by Ashton and colleagues,⁴⁸ Patz,²¹ and preclinical studies before the FDA approval of anti-VEGF agents in adult diseases. Because it is not possible to safely obtain tissue or vitreous samples from the preterm infant eye to study ROP without risks of bleeding, cataract, or inoperable retinal detachment,⁴² animal models of OIR have been used. It is important to know strengths and limitations of different models when reviewing the evidence. First, all models use newborn, and not premature, animals, unlike the human infant with ROP. Second, most studies have used the mouse OIR model,⁴⁹ which exposes newborn mice to high oxygen levels. This model may reflect ROP in places that lack resources to regulate oxygen⁵⁰ or ROP that occurred in the United States and United Kingdom in the 1950s^{51,52} but is not as representative of ROP in places where oxygen is regulated (Table 5). A benefit of the mouse OIR model is the ability to use transgenic mice to study mechanisms of angiogenesis, high oxygen, and relative hypoxia. In contrast, the rat 50/10 OIR model ("rat ROP model")^{53,54} reflects the conditions associated with the pathogenesis of human ROP because it reproduces arterial oxygen levels of preterm infants with severe ROP.^{32,55} It also causes extrauterine growth restriction.⁵⁶ It is the most representative model of ROP today.⁵² Previously, mechanistic studies relied mainly on pharmacologic manipulations, but recently, methods have been developed using a gene therapy approach that permits knockdown of VEGF in specific cells in the retina that overexpress VEGF.^{57,58} These new approaches have been valuable in understanding the mechanisms whereby overexpressed VEGF causes aberrant intravitreal angiogenesis as well as the effect of various methods to inhibit VEGF bioactivity on developing retinal vasculature and developing systemic organs.

THE BEVACIZUMAB ELIMINATES THE ANGIOGENIC THREAT OF RETINOPATHY OF PREMATURITY STUDY

Although several clinical series had been reported previously, the Bevacizumab Eliminates the Angiogenic Threat of Retinopathy of Prematurity (BEAT-ROP) was the first

Table 3 Current management of ROP	
Screening guidelines	
US	≤30 wk GA or ≤1500 g BW (and preterm infants with an unstable clinical course) ⁴⁵
UK	≤31 wk GA or ≤1500 g BW
Canada	≤30 6/7 wk GA or ≤1250 g
Timing of screening and examinations	
First examination at 4–6 wk chronologic age or 31 wk postgestational age	
Repeated examinations recommended by examining ophthalmologist based on retinal findings and suggested schedule	
Type of examination	
Dilated binocular indirect ophthalmoscopy	
Ongoing studies of validation and reliability of retinal imaging as a potential telemedicine alternative for screening	
Parameters of ROP determined in examinations	
Zone: Area of retinal vascularization	I: Retinal vasculature extends within a circle centered on the optic nerve, the radius of which is twice the optic nerve-to-macula distance II: Retinal vasculature extends beyond zone I within the limits of a circular area, the radius of which is the distance from the optic nerve to the nasal ora serrata III: The remaining area outside zones I or II
Stage: Disease severity (Fig. 1)	1: Line 2: Ridge (with volume) 3: IVNV 4: Partial retinal detachment 5: Total retinal detachment Plus disease, dilation and tortuosity of retinal vessels
Treatment	
Application of laser to peripheral avascular retina for type 1 ROP (high-risk prethreshold)	Zone I: stage 3 Zone I: any stage with plus disease Zone II: stage 2 or 3 with plus disease
In some cases, anti-VEGF for stage 3 and plus disease in zone I	Additional study needed to determine dose, safety, and type of anti-VEGF
Visual rehabilitation	Refractive correction very often needed for associated refractive errors (ametropia and anisometropia); protective eyewear and low vision aids

Abbreviations: BW, birth weight; GA, gestational age.

published clinical trial that tested intravitreal anti-VEGF antibody, bevacizumab (0.625 mg in 0.025 mL), compared with laser treatment in 150 infants.⁵⁹ Infants rather than eyes were enrolled to reduce confounding from crossover effects of the antibody. A benefit for infants with zone I/posterior zone II, stage 3+ ROP was reported in patients ($P = .003$). In many of these eyes, physiologic vascularization progressed to

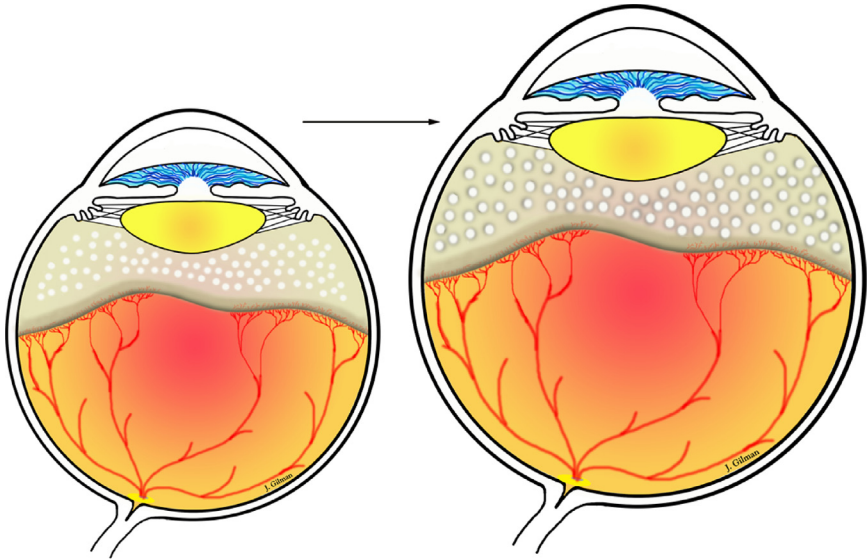


Fig. 1. As the eye grows, there is increased avascular retina peripherally and thus an increase in area between laser spots. Avascular retina leads to hypoxia, which can stimulate angiogenic signaling through hypoxia-inducible factors that translocate to the nucleus and bind to DNA promoter to cause transcription of multiple angiogenic factors, like VEGF, erythropoietin, angiopoietins, as examples.

zone II after intravitreal angiogenesis was inhibited. The study was too small to assess safety and effects on future development of brain and other tissues. The study also did not address dose or anti-VEGF agent. The study follow-up was continued through 54 weeks' postgestational age. However, later studies of infants treated with intravitreal bevacizumab and followed through 60 weeks' postgestational age reported associated complications, including persistent peripheral avascular retina, new intravitreal neovascularization (IVNV), retinal detachment, and macular dragging.^{16,60} Other studies reported reduced serum VEGF in infants who received bevacizumab or ranibizumab even 2 weeks following the intravitreal injection.^{13,14} Although there is some promise with anti-VEGF treatment, there is clinical risk of poor outcome and safety concerns potentially from systemic reduction of VEGF. Better treatments are needed.

CONSIDERATION OF ANTI-VASCULAR ENDOTHELIAL GROWTH FACTOR AGENTS IN SEVERE RETINOPATHY OF PREMATURITY: KNOWLEDGE FROM ANIMAL MODELS

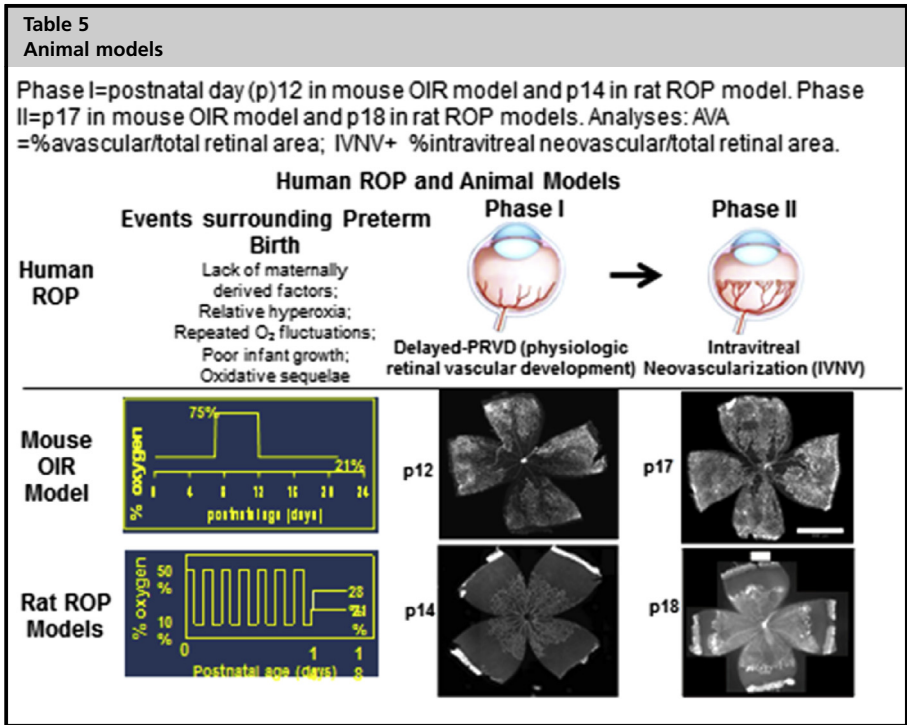
Pro: Evidence That Inhibiting Vascular Endothelial Growth Factor Inhibits Intravitreal Angiogenesis in Severe Retinopathy of Prematurity

ROP has been characterized by 2 phases based on clinical observations and animal models.^{48,61,62} Human ROP also has a third, fibrovascular phase, in which retinal detachment occurs. Few animal models reflect this. The first "epidemic" of ROP occurred in the United States and the United Kingdom in the 1950s. Using a model in kittens, Ashton described phase 1 as high oxygen-induced vaso-obliteration and phase 2 as later hypoxia-induced vasoproliferation.⁴⁸ Since then, with changes in neonatal practices and technologic improvements in oxygen regulation and monitoring, the 2-phase description has been refined.⁵² In phase I ROP, mainly peripheral avascular retina occurs from a delay in physiologic retinal vascular development

Table 4

Major clinical trials in ROP

Trial (Enrollment)	Criteria	Number Enrolled	Endpoint (Follow-up)	Outcome Measures	Results
CRYO-ROP (1/1/86–1/22/88)	<1251 g BW; survived 28 d of life; no major systemic or ocular anomalies	4099 (291 with threshold ROP randomized to cryotherapy or observation, 254 analyzed at 15 y)	Reports at 3 mo, 1 through 15 y	Visual function; structural findings	At 15 y; 44.7% cryotherapy vs 64.3% observation had <20/200 and 30.0% vs 51.9% had unfavorable structural outcomes; <i>P</i> <.001
ETROP (10/9–10/02)	<1251 g BW; prethreshold ROP	828 infants (730 studied); 401 high-risk prethreshold (≥15% risk of unfavorable outcome = type 1 ROP), 329 low risk (<15% risk = type 2 ROP)	9 mo, 6 y early treatment (prethreshold) vs conventional (threshold) ROP	Vision at 9 mo (Teller Acuity Cards) and 6 y follow-up; secondary outcomes retinal structure, myopia, amblyopia, strabismus	Early treatment, reduced unfavorable visual outcome (19.8%–14.3%, <i>P</i> = .01) at 9 mo and for type 1 ROP at 6 y (16.4% early vs 25.2% conventional); significantly reduced unfavorable outcome (15.6% vs 9.0%; <i>P</i> <.001 at 9 mo and 15.2%–8.9% at 6 y)
BEAT-ROP (3/13/08–8/4/10)	≤ 1500 g BW, ≤30 wk, stage 3+ ROP in zone I or zone II	150 infants (67 with zone I, 83 with posterior zone II) enrolled, 143 survived; 75 randomized to conventional laser, 75 to intravitreal bevacizumab	54 wk PMA	Recurrence of ROP (primary outcome), interval from treatment to recurrence, need for surgery	Reduced recurrence of stage 3 ROP in zone I ROP after intravitreal bevacizumab (4%) compared with laser (22%); no effect for zone II disease



(PRVD)⁵² and, in places with insufficient resources to regulate oxygen, hyperoxia-induced vaso-attenuation.⁵⁰ With delayed PRVD but continued eye growth, the peripheral avascular retina can increase in area (eye growth can also expand avascular retina between laser spots and is hypothesized to create an additional hypoxic stimulus for the development of recurrent intravitreal angiogenesis after laser treatment in very small immature preterm infants; see Fig. 1).⁶³

In phase II ROP, IVNV occurs from hypoxia or potentially oxidative stress or metabolic demands.^{49,52,64,65} VEGF is an important angiogenic factor in both PRVD and in IVNV, and inhibition of its bioactivity would be predicted to inhibit both normal (PRVD) and pathologic (IVNV) angiogenesis. However, evidence from OIR models suggests that inhibition of VEGF signaling to a certain degree may not adversely inhibit PRVD and still reduce IVNV (Table 6). From the mouse OIR model, initial

Table 6
Pros and cons for inhibiting VEGF signaling in ROP

Pros	Cons
Orders developing retinal angiogenesis	Reduces serum VEGF in infants
Preclinical studies showing effects in models of OIR	Recurrent intravitreal NV in preterm infants occurs often much later than after laser
	Survival factor in adult homeostasis and in developing vascular and neural beds
	Animal models show reduced body weight gain, loss of retinal capillary support, cell death in photoreceptors, reduced serum VEGF, recurrent IVNV

observations suggested that the central vaso-obiterated retina induced by high oxygen was not increased after an anti-VEGF neutralizing antibody was delivered into the vitreous at a dose that was found to effectively inhibit IVNV.⁶⁶ Later, studies by Geisen and colleagues⁶⁷ and Budd and colleagues⁶⁸ used quantitative methods in the rat 50/10 OIR model and found that neither a neutralizing antibody to VEGF nor a VEGFR2 tyrosine kinase inhibitor increased the avascular retinal area at doses that significantly inhibited IVNV. Because a single allele knockout of VEGF or one of its splice variants or receptors is lethal in mice, studies done in an embryonic stem cell model were performed to understand the mechanisms whereby inhibition of an angiogenic factor would reduce intravitreal, but not systemic, intraretinal angiogenesis. Using a knockout of VEGFR1 (*flt1*) in the embryonic stem cell model permitted VEGF to trigger signaling mainly through VEGFR2 by overactivating the receptor. This model demonstrated that overactivation of VEGFR2 disordered angiogenesis and caused a pattern of growth similar in appearance to IVNV. The pattern of growth could be rescued and physiologic vascularization restored with the addition of a transgene of VEGFR1 containing a CD31 promoter to target endothelial cells.⁶⁹ This work demonstrated that not only overactivated VEGFR2 but also VEGFR2 specifically in endothelial cells was responsible for aberrant angiogenesis. Then, in the rat 50/10 OIR model, the relationship between the long axis of lectin-labeled retinal vessels and the anti-phospho-histone H3-labeled cleavage planes of dividing endothelial cells to a tortuosity index in lectin stained arteries and veins was determined following treatment with a neutralizing antibody to rat VEGF compared with a nonimmune immunoglobulin G (IgG) control. The neutralizing antibody was found to reduce dilation and tortuosity in the OIR model.⁷⁰ This study supported the development of the hypothesis that overactivation of VEGFR2 disordered dividing endothelial cells, allowing them to grow in a pattern similar to IVNV and that by down-regulating VEGFR2 signaling, intraretinal vascularization occurred. More recently, a lentivector gene therapy approach was developed in the rat 50/10 OIR model to reduce overexpressed VEGF in Müller cells, where the VEGF signal was found.⁵⁷ A short hairpin RNA to knockdown vascular endothelial growth factor A (VEGFA) in Müller cells only was introduced into the model and found to reduce VEGFR2 signaling in endothelial cells⁵⁷ and significantly inhibit IVNV, but not PRVD. Also, down-regulating overactivated VEGFR2 in endothelial cells ordered the cleavage planes of dividing endothelial cells into a physiologic pattern, promoting vessel elongation.⁷¹ Thus, experimental evidence supports the premise that inhibiting the VEGF/VEGFR2 signaling cascade not only inhibits IVNV but also permits PRVD by restoring the normal orientation to dividing endothelial cells; this suggests that regulating VEGFR2 to physiologic signaling may be a promising approach to reduce IVNV without interfering with PRVD. However, VEGF is also important in physiologic development and homeostasis of retinal neurons and glial cells,^{10,58} so efforts to target signaling effectors downstream of VEGF/VEGFR2 activation appear important.

Con: Evidence That Vascular Endothelial Growth Factor Inhibition Can Lead to Harm

Most studies regarding retinal vascular development have been done in animals. Evidence concerning vascular development exists up through 22 weeks' gestation in human preterm infant eyes. Based on careful immunohistochemical studies, retinal vascularization occurred through a process of vasculogenesis at about 12 weeks' gestation in the human embryonic retina and continued through at least 22 weeks' gestation, allowing for inner retinal plexus vascularization through zone I.⁷² Vasculogenesis is the formation of blood vessels de novo from endothelial precursor cells or angioblasts.

After 22 weeks, it is less clear how the retinal vasculature extends to the ora serrata because of the difficulty in obtaining human eyes in adequate condition for study, but based on mice and other animals that vascularize their retinas after birth, vascularization is thought to occur through angiogenesis (ie, the budding of new vessels from existing blood vessels). Both processes appear to involve VEGF.⁷³ Besides its role in angiogenesis, VEGF is also a survival factor for other cells of the retina, including neurons, and is important in other organ development.¹² These issues are important when considering anti-VEGF agents in the developing preterm infant. However, many infants at risk of severe ROP also have delayed central nervous system development. Therefore, sorting out the effects of anti-VEGF treatment for ROP from prematurity and periventricular leukomalacia may be difficult.

Since the BEAT-ROP study, reports of reduced serum VEGF levels have been reported for at least 2 weeks following intravitreal anti-VEGF agents.^{13,14} There have also been numerous reports on associations of intravitreal anti-VEGF agents⁸ with prolonged, persistent avascular retina, recurrent IVNV, and even blindness from retinal detachment.^{16,74} Early studies reported that the risk of ROP following laser or cryotherapy generally was removed after about 45 weeks' postgestational age.⁷⁵ However, recurrences after anti-VEGF were reported at 60 weeks' postgestational age.⁶⁰ The causes of the recurrences remain unclear. In one study using the rat 50/10 OIR model, investigators found recurrence after higher doses of anti-VEGF agents in association with other angiogenic factors, including erythropoietin.⁷⁶

In another study, PRVD in retinal flat mounts was determined in retinal plexi by 2 methods.⁷¹ The first method was the ratio of the areas of vascularized retina, determined by extent of coverage of lectin-stained retinal vessels, to total retina. In the second method, the number of pixels of fluorescence from lectin-stained vessels was determined and a ratio was created between pixels of lectin fluorescence to total retinal area. The latter measurement took into account both extent of retinal vascularization and capillary density. Two treatments were used: a broad intravitreal antibody to VEGF or a lentivector gene therapy approach to reduce overexpressed VEGF with an shRNA to VEGFA in Müller cells. Each treatment was compared with its respective control, either intravitreal IgG for the intravitreal anti-VEGF antibody or a control shRNA to the nonmammalian gene, luciferase, for the lentivector gene therapy strategy. Compared with respective controls, each treatment reduced IVNV 4-fold and did not adversely affect PRVD determined by extent of lectin-stained vascular coverage. However, the broad intravitreal anti-VEGF antibody reduced pixels of lectin fluorescence and, therefore, capillary density in retinal vascular plexi, whereas targeted VEGF knockdown did not.⁷¹ In addition, intravitreal anti-VEGF antibody also reduced body weight gain⁷⁶ and serum VEGF levels, whereas targeted VEGF knockdown in Müller cells did not.⁵⁷ These results suggest that targeted VEGF knockdown in Müller cells may be safer than broad anti-VEGF inhibition. Also, VEGF appeared to be important for already developed retinal capillaries, and these studies suggested that reduced capillary density may be a possible mechanism for late recurrent IVNV reported after intravitreal anti-VEGF antibody.⁷⁶

In an additional study, the question was posed whether knockdown of a VEGF splice variant might be safer than knockdown of the full VEGFA sequence. In the rat 50/10 OIR model, a gene therapy approach was used to knockdown VEGF or a splice variant in Müller cells using shRNAs to VEGFA, VEGF₁₆₄ splice variant, or luciferase as a control.⁵⁸ Initially, shRNAs to either VEGFA or VEGF₁₆₄ significantly reduced IVNV compared with control but only the VEGF₁₆₄ knockdown maintained IVNV inhibition at the later time point studied. Also, targeted Müller cell knockdown of VEGFA caused increased TUNEL+ cell death and retinal thinning of the outer

nuclear layer, whereby the photoreceptor nuclei are located. From these studies, targeted knockdown of VEGFA in Müller cells following repeated fluctuations in oxygenation appears safer than broad intravitreal anti-VEGF antibody, but may still cause photoreceptor loss. (Photoreceptors, ie, rods and cones, are essential to visual development and to vision, generally.) Targeting Müller cell VEGF₁₆₄ may therefore be potentially safer. However, more studies are needed to determine the long-term effects of targeted knockdown of VEGF splice variants on visual and retinal function and structure. Also, it appears that measurements of body weight gain, vascular coverage or persistent avascular retina, and recurrence of IVNV are insufficient to determine safety in preterm infant retinas receiving anti-VEGF treatment because none of these was adversely affected by knockdown of either VEGFA or VEGF₁₆₄ in Müller cells.

As infants become older, examination of the peripheral retina without anesthesia becomes more difficult and less accurate. Several clinicians may perform laser treatment of the peripheral avascular retina after anti-VEGF agents with signs of recurrence or when the infant grows large enough that the ability to perform an adequate retinal examination without anesthesia is impaired. However, the question whether persistent avascular retina should be treated is difficult to address, because all OIR models have regression of IVNV and vascularization of the avascular retina. It is possible that some human preterm retinas may be incapable of supporting retinal vasculature, but in other eyes, vascularization might occur or avascular retina might persist without ever causing IVNV (see [Table 6](#)).

CONSIDERATIONS REGARDING ADULT/PRETERM INFANT SIZE AND DOSE CONSIDERATIONS

No anti-VEGF agent has been FDA-approved for treatment of ROP. Ranibizumab (Genentech) or aflibercept (Regeneron) are the FDA-approved agents for adult eye diseases. The BEAT-ROP clinical trial used bevacizumab, which has not been FDA-approved for any eye disease, but has been tested head-to-head with ranibizumab in a clinical trial for adult AMD and shown to be noninferior.⁷⁷ Bevacizumab is a humanized monoclonal antibody to VEGF that was tested as an anticancer agent but was not formally tested or formulated for use in the eye. Ranibizumab was tested for use in the eye and is the Fab fragment of a monoclonal anti-VEGF antibody. Treatment with bevacizumab is approximately 1/20th the cost of ranibizumab. The dose of either ranibizumab (0.5 mg) or bevacizumab (1.25 mg) is injected into the adult eye in a volume of 0.05 mL. Because no pharmacologic formulation is available for preterm infant eyes, the same dosing and volume have often been chosen because of the difficulty in drawing up smaller volumes accurately and the lack of knowledge as to appropriate dose in the preterm infant eye.

It is unknown what a normal VEGF level is in the blood or vitreous in a preterm infant who does not develop ROP. There also is no way to safely measure VEGF in the vitreous of a preterm infant, so the dose to neutralize VEGF cannot currently be determined for individual infants or eyes. Both ranibizumab and bevacizumab can reduce serum VEGF levels in preterm infants,^{13,14} even though in adults, a study comparing bevacizumab, ranibizumab, and pegaptanib (an aptamer to VEGF splice variant, VEGF₁₆₅) found that only bevacizumab reduced serum VEGF.⁷⁸ The different concentrations of serum VEGF between adults and preterm infants may in part reflect the differences in eye/blood volumes. A preterm infant's vitreous volume is about 1 mL, whereas an adult's is approximately 4 mL. However, a preterm infant's blood volume is about 120 mL at a postgestational age of 35 to 39 weeks when severe ROP occurs,

and an adult's blood volume is usually more than 5000 mLs. Therefore, even though the concentration of active VEGF is not known, there is less effect from dilution of the drug in the preterm infant's blood volume compared with the adult's blood volume. In addition, ROP develops often 2 or 3 months after birth. In the United States, an infant that develops severe ROP is often much smaller (and blood volume less) than an infant with severe ROP in other countries where ROP occurs in larger and older infants. Therefore, the safety profile from studies that test anti-VEGF in severe ROP from these countries may not be comparable to that of the United States. Anti-angiogenic treatment may need to be individualized based on the eye and infant. These potential considerations are rarely discussed when comparing anti-VEGF treatment outcomes or side effects in infants from developing nations or the United States.

GUIDELINES IF CONSIDERING ANTI-VASCULAR ENDOTHELIAL GROWTH FACTOR TREATMENT

Bevacizumab is not FDA-approved. However, there are more studies reported on bevacizumab than on ranibizumab, for which there is no clinical trial for ROP reported to date (Table 7). However, there have been opinions as to which anti-VEGF agent is optimal. Bevacizumab causes longer-term reduction in systemic VEGF levels in adults compared with ranibizumab and, therefore, may be more damaging to the preterm infant. However, in preterm infants, ranibizumab also reduced serum VEGF. Ranibizumab penetrates more deeply into the eye, and there is concern this might affect the choroidal circulation, which provides oxygen to the developing retina and is thought important in the pathophysiology of ROP.⁷⁹ The American Academy of Pediatrics

Indications for Use	Informed Consent	Log	Follow-up
Clinical trial BEAT-ROP found effect in zone I, Stage 3+ disease	Agents not FDA approved	Age, date, eye treated, dose and agent used, volume	Monitor weekly after treatment until vascularization is complete to ora serrata
No clinical trial evidence of effect with less severe ROP	Questions remain regarding long-term safety, dose, timing, visual outcomes and long-term effects, including systemically	Communicate with neonatologist and ophthalmologist during transfer or discharge	Longer follow-up is needed because recurrences following bevacizumab occurred later than laser treatment
		Communication with parents is essential, including the need for follow-up examinations and risks, and documentation must be performed	Unknown what to do if avascular retina persists after 60 wk chronologic age when awake examinations are difficult; consider ablative treatment

Data from Fierson WM, American Academy of Pediatrics Section on Ophthalmology, American Academy of Ophthalmology, et al. Screening examination of premature infants for retinopathy of prematurity. *Pediatrics* 2013;131:189–95.

and the American Academy of Ophthalmology have developed guidelines for ROP and the consideration of anti-VEGF treatment.⁴⁵ Because no clinical trial has been performed for ranibizumab at the time of this writing, the recommendations are based on bevacizumab. If bevacizumab is contemplated in cases in which corneal, lenticular, or vitreous opacities preclude treatment with laser, it should only be used for stage 3+ ROP in zone I and not for zone II ROP. Also, a detailed informed consent outlining the potential risks is required. If bevacizumab is used, infants must be examined weekly until full vascularization of the retina occurs. Follow-up must be performed for a longer period of time than after conventional laser treatment, because recurrent stage 3 ROP has been reported at later time points than after conventional laser (16 ± 4.6 weeks vs 6.2 ± 5.7 weeks). Also, a log of infants treated and dates of treatment is recommended. Good and clear communication between the treating ophthalmologist and neonatologist is essential on transfer or discharge.

FUTURE

Studies are ongoing to determine pharmacologic approaches that target signaling downstream of VEGF receptors to safely and effectively inhibit pathologic angiogenesis without interfering with ongoing retinal vascular development. More clinical studies are needed to determine potential safe doses of anti-VEGF agents, and dose escalation studies are being considered. In addition, studies to promote normal retinal vascular development may be considered through the use of nutrients, such as peptides,⁸⁰ omega-3 fatty acids,⁸¹ and growth factors, including insulin-like growth factor 1.⁸² Clinical studies are also being performed testing early use of erythropoietin on later cognitive function. There is some evidence that erythropoietin can be angiogenic in preterm infants.⁸³ A recent clinical study in preterm infants testing darbepoietin, a form of erythropoietin, reported no increased, but also no reduced risk of severe ROP; however, numbers were small.⁸⁴ Further studies are warranted. Because heritability may be associated with ROP,²⁰ studies on the association of severe ROP and genetic variants are needed. Potentially, phenotype/genotype studies may identify infants at great risk of severe ROP and also help in understanding the pathophysiology of disease so as to develop new treatments.

REFERENCES

1. Churchill AJ, Carter JG, Lovell HC, et al. VEGF polymorphisms are associated with neovascular age-related macular degeneration. *Hum Mol Genet* 2006;15:2955–61.
2. Bird AC. Therapeutic targets in age-related macular disease. *J Clin Invest* 2010;120:3033–41.
3. Yang Z, Wang H, Jiang Y, et al. VEGFA activates erythropoietin receptor and enhances VEGFR2-mediated pathological angiogenesis. *Am J Pathol* 2014;184:1230–9.
4. Aiello LP, Avery RL, Arrigg PG, et al. Vascular endothelial growth factor in ocular fluid of patients with diabetic retinopathy and other retinal disorders. *N Engl J Med* 1994;331:1480–7.
5. Nicholson B, Schachat A. A review of clinical trials of anti-VEGF agents for diabetic retinopathy. *Graefes Arch Clin Exp Ophthalmol* 2010;248:915–30.
6. Cooke RW, Drury JA, Mountford R, et al. Genetic polymorphisms and retinopathy of prematurity. *Invest Ophthalmol Vis Sci* 2004;45:1712–5.
7. Mititelu M, Chaudhary KM, Lieberman RM. An evidence-based meta-analysis of vascular endothelial growth factor inhibition in pediatric retinal diseases: part 1. Retinopathy of prematurity. *J Pediatr Ophthalmol Strabismus* 2012;49:332–40.

8. Mintz-Hittner HA, Kennedy KA, Chuang AZ. Efficacy of intravitreal bevacizumab for stage 3+ retinopathy of prematurity. *N Engl J Med* 2011;364:603–15.
9. Saint-Geniez M, Kurihara T, Sekiyama E, et al. An essential role for RPE-derived soluble VEGF in the maintenance of the choriocapillaris. *Proc Natl Acad Sci U S A* 2009;106:18751–6.
10. Saint-Geniez M, Maharaj AS, Walshe TE, et al. Endogenous VEGF is required for visual function: evidence for a survival role on muller cells and photoreceptors. *PLoS One* 2008;3:e3554.
11. Rofagha S, Bhisitkul RB, Boyer DS, et al. Seven-year outcomes in ranibizumab-treated patients in ANCHOR, MARINA, and HORIZON: a Multicenter Cohort Study (SEVEN-UP). *Ophthalmology* 2013;120:2292–9.
12. Nishijima K, Ng YS, Zhong L, et al. Vascular endothelial growth factor-A is a survival factor for retinal neurons and a critical neuroprotectant during the adaptive response to ischemic injury. *Am J Pathol* 2007;171:53–67.
13. Sato T, Wada K, Arahori H, et al. Serum concentrations of bevacizumab (Avastin) and vascular endothelial growth factor in infants with retinopathy of prematurity. *Am J Ophthalmol* 2012;153:327–33.
14. Hoerster R, Muether P, Dahlke C, et al. Serum concentrations of vascular endothelial growth factor in an infant treated with ranibizumab for retinopathy of prematurity. *Acta Ophthalmol* 2013;91:e74–5.
15. Hu J. Reactivation of retinopathy of prematurity after bevacizumab injection. *Arch Ophthalmol* 2012;130:1000–6.
16. Patel RD, Blair MP, Shapiro MJ, et al. Significant treatment failure with intravitreal bevacizumab for retinopathy of prematurity. *Arch Ophthalmol* 2012;130:801–2.
17. Gilbert C. Retinopathy of prematurity: a global perspective of the epidemics, population of babies at risk and implications for control. *Early Hum Dev* 2008;84:77–82.
18. Kong L, Fry M, Al-Samarraie M, et al. An update on progress and the changing epidemiology of causes of childhood blindness worldwide. *J AAPOS* 2012;16:501–7.
19. Kemper AR, Freedman SF, Wallace DK. Retinopathy of prematurity care: patterns of care and workforce analysis. *J AAPOS* 2008;12:344–8.
20. Bizzarro MJ, Hussain N, Jonsson B, et al. Genetic susceptibility to retinopathy of prematurity. *Pediatrics* 2006;118:1858–63.
21. Patz A. Studies on retinal neovascularization. Friedenwald Lecture. *Invest Ophthalmol Vis Sci* 1980;19:1133–8.
22. Ashton N, Cook C. Direct observation of the effect of oxygen on developing vessels: preliminary report. *Br J Ophthalmol* 1954;38:433–40.
23. Ashton N. Editorial: retrolental fibroplasia now retinopathy of prematurity. *Br J Ophthalmol* 1984;68:689.
24. Shweiki D, Itin A, Soffer D, et al. Vascular endothelial growth factor induced by hypoxia may mediate hypoxia-initiated angiogenesis. *Nature* 1992;359:843–5.
25. Group TS-RMS. Supplemental therapeutic oxygen for prethreshold retinopathy of prematurity (STOP-ROP), a randomized, controlled trial. I: primary outcomes. *Pediatrics* 2000;105:295–310.
26. Gaynon MW. Rethinking stop-ROP: is it worthwhile trying to modulate excessive VEGF levels in prethreshold ROP eyes by systemic intervention? A review of the role of oxygen, light adaptation state, and anemia in prethreshold ROP. *Retina* 2006;26:S18–23.
27. SUPPORT Study Group of the Eunice Kennedy Shriver NICHD Neonatal Research Network, Finer NN, Carlo WA, et al. Early CPAP versus surfactant in extremely preterm infants. *N Engl J Med* 2010;362:1970–9.

28. Stenson BJ, Tarnow-Mordi WO, Darlow BA, et al. Oxygen saturation and outcomes in preterm infants. *N Engl J Med* 2013;368:2094–104.
29. Schmidt B, Whyte RK, Asztalos EV, et al. Effects of targeting higher vs lower arterial oxygen saturations on death or disability in extremely preterm infants: a randomized clinical trial. *JAMA* 2013;309:2111–20.
30. Hartnett ME, Lane RH. Effects of oxygen on the development and severity of retinopathy of prematurity. *J AAPOS* 2013;17:229–34.
31. Owen L, Hartnett ME. Current concepts of oxygen management and ROP. *J Ophthalmic Vis Res* 2014;9:94–100.
32. York JR, Landers S, Kirby RS, et al. Arterial oxygen fluctuation and retinopathy of prematurity in very-low-birth-weight infants. *J Perinatol* 2004;24:82–7.
33. Hauspurg AK, Allred EN, Vanderveen DK, et al. Blood gases and retinopathy of prematurity: the ELGAN Study. *Neonatology* 2011;99:104–11.
34. Saito Y, Geisen P, Uppal A, et al. Inhibition of NAD(P)H oxidase reduces apoptosis and avascular retina in an animal model of retinopathy of prematurity. *Mol Vis* 2007;13:840–53.
35. Budd SJ, Thompson H, Hartnett ME. Association of retinal vascular endothelial growth factor with avascular retina in a rat model of retinopathy of prematurity. *Arch Ophthalmol* 2010;128:1014–21.
36. Hellstrom A, Hard AL, Engstrom E, et al. Early weight gain predicts retinopathy in preterm infants: new, simple, efficient approach to screening. *Pediatrics* 2009;123:e638–45.
37. Penn JS. Oxygen-induced retinopathy in the rat: possible contribution of peroxidation reactions. *Doc Ophthalmol* 1990;74:179–86.
38. Phelps DL. Vitamin E and retinopathy of prematurity: the clinical investigator's perspective on antioxidant therapy: side effects and balancing risks and benefits. *Birth Defects Orig Artic Ser* 1988;24:209–18.
39. Raju TN, Langenberg P, Bhutani V, et al. Vitamin E prophylaxis to reduce retinopathy of prematurity: a reappraisal of published trials. *J Pediatr* 1997;131:844–50.
40. Early Treatment for Retinopathy of Prematurity Cooperative Group. Revised indications for the treatment of retinopathy of prematurity: results of the early treatment for retinopathy of prematurity randomized trial. *Arch Ophthalmol* 2003;121:1684–94.
41. Cryotherapy for Retinopathy of Prematurity Cooperative Group. Multicenter trial of cryotherapy for retinopathy of prematurity. Snellen visual acuity and structural outcome at 5 1/2 years after randomization. *Arch Ophthalmol* 1996;114:417–24.
42. Hartnett ME. Features associated with surgical outcome in patients with stages 4 and 5 retinopathy of prematurity. *Retina* 2003;23:322–9.
43. Wong RK, Ventura CV, Espiritu MJ, et al. Training fellows for retinopathy of prematurity care: a web-based survey. *J AAPOS* 2012;16:177–81.
44. Eills AL, Holmes JM, Astle WF, et al. Telemedicine approach to screening for severe retinopathy of prematurity: a pilot study. *Ophthalmology* 2003;110:2113–7.
45. Fierson WM, American Academy of Pediatrics Section on Ophthalmology, American Academy of Ophthalmology, et al. Screening examination of premature infants for retinopathy of prematurity. *Pediatrics* 2013;131:189–95.
46. Coats DK. Retinopathy of prematurity: involution, factors predisposing to retinal detachment, and expected utility of preemptive surgical reintervention. *Trans Am Ophthalmol Soc* 2005;103:281–312.
47. Hartnett ME, McCole JM. Retinal features predictive of progressive stage 4 retinopathy of prematurity. *Retina* 2004;24:237–41.

48. Ashton N, Ward B, Serpell G. Effect of oxygen on developing retinal vessels with particular reference to the problem of retrolental fibroplasia. *Br J Ophthalmol* 1954;38:397–430.
49. Smith LE, Wesolowski E, McLellan A, et al. Oxygen-induced retinopathy in the mouse. *Invest Ophthalmol Vis Sci* 1994;35:101–11.
50. Shah PK, Narendran V, Kalpana N. Aggressive posterior retinopathy of prematurity in large preterm babies in South India. *Arch Dis Child Fetal Neonatal Ed* 2012;97:F371–5.
51. Patz A. Oxygen studies in retrolental fibroplasia. *Am J Ophthalmol* 1954;38:291–308.
52. Hartnett ME, Penn JS. Mechanisms and management of retinopathy of prematurity. *N Engl J Med* 2012;367:2515–26.
53. Penn JS, Henry MM, Tolman BL. Exposure to alternating hypoxia and hyperoxia causes severe proliferative retinopathy in the newborn rat. *Pediatr Res* 1994;36:724–31.
54. Berkowitz BA, Zhang W. Significant reduction of the panretinal oxygenation response after 28% supplemental oxygen recovery in experimental ROP. *Invest Ophthalmol Vis Sci* 2000;41:1925–31.
55. Cunningham S, Fleck BW, Elton RA, et al. Transcutaneous oxygen levels in retinopathy of prematurity. *Lancet* 1995;346:1464–5.
56. Holmes JM, Duffner LA. The effect of postnatal growth retardation on abnormal neovascularization in the oxygen exposed neonatal rat. *Curr Eye Res* 1996;15:403–9.
57. Wang H, Smith GW, Yang Z, et al. Short hairpin RNA-mediated knockdown of VEGFA in muller cells reduces intravitreal neovascularization in a rat model of retinopathy of prematurity. *Am J Pathol* 2013;183:964–74.
58. Jiang Y, Wang H, Culp D, et al. Targeting Müller cell-derived VEGF164 to reduce intravitreal neovascularization in the rat model of retinopathy of prematurity. *Invest Ophthalmol Vis Sci* 2014;55:824–31.
59. Mintz-Hittner HA. Treatment of retinopathy of prematurity with vascular endothelial growth factor inhibitors. *Early Hum Dev* 2012;88:937–41.
60. Hu J, Blair MP, Shapiro MJ, et al. Reactivation of retinopathy of prematurity after bevacizumab injection. *Arch Ophthalmol* 2012;130:1000–6.
61. Smith LE. Through the eyes of a child: understanding retinopathy through ROP the Friedenwald lecture. *Invest Ophthalmol Vis Sci* 2008;49:5177–82.
62. An International Committee for the Classification of Retinopathy of Prematurity. The international classification of retinopathy of prematurity revisited. *Arch Ophthalmol* 2005;123:991–9.
63. Hartnett ME. Retinopathy of prematurity: a template for studying retinal vascular disease. In: Werner JS, Chalupa LM, editors. *The New Visual Neurosciences*. Cambridge (MA): MIT Press; 2014. p. 1483–501.
64. Byfield G, Budd S, Hartnett ME. The role of supplemental oxygen and JAK/STAT signaling in intravitreal neovascularization in a ROP rat model. *Invest Ophthalmol Vis Sci* 2009;50:3360–5.
65. Saito Y, Uppal A, Byfield G, et al. Activated NAD(P)H oxidase from supplemental oxygen induces neovascularization independent of VEGF in retinopathy of prematurity model. *Invest Ophthalmol Vis Sci* 2008;49:1591–8.
66. Sone H, Kawakami Y, Kumagai AK, et al. Effects of intraocular or systemic administration of neutralizing antibody against vascular endothelial growth factor on the murine experimental model of retinopathy. *Life Sci* 1999;65:2573–80.
67. Geisen P, Peterson L, Martiniuk D, et al. Neutralizing antibody to VEGF reduces intravitreal neovascularization and does not interfere with vascularization of avascular retina in an ROP model. *Mol Vis* 2008;14:345–57.

68. Budd S, Byfield G, Martiniuk D, et al. Reduction in endothelial tip cell filopodia corresponds to reduced intravitreal but not intraretinal vascularization in a model of ROP. *Exp Eye Res* 2009;89:718–27.
69. Zeng G, Taylor SM, McColm JR, et al. Orientation of endothelial cell division is regulated by VEGF signaling during blood vessel formation. *Blood* 2007;109:1345–52.
70. Hartnett ME, Martiniuk D, Byfield G, et al. Neutralizing VEGF decreases tortuosity and alters endothelial cell division orientation in arterioles and veins in a rat model of ROP: relevance to plus disease. *Invest Ophthalmol Vis Sci* 2008;49:3107–14.
71. Wang H, Yang Z, Jiang Y, et al. Quantitative analyses of retinal vascular area and density after different methods to reduce VEGF in a rat model of retinopathy of prematurity. *Invest Ophthalmol Vis Sci* 2014;55:737–44.
72. Hasegawa T, McLeod DS, Prow T, et al. Vascular precursors in developing human retina. *Invest Ophthalmol Vis Sci* 2008;49:2178–92.
73. Chan-Ling T, Gock B, Stone J. The effect of oxygen on vasoformative cell division: evidence that 'physiological hypoxia' is the stimulus for normal retinal vasculogenesis. *Invest Ophthalmol Vis Sci* 1995;36:1201–14.
74. Jalali S, Balakrishnan D, Zeynalova Z, et al. Serious adverse events and visual outcomes of rescue therapy using adjunct bevacizumab to laser and surgery for retinopathy of prematurity. The Indian Twin Cities Retinopathy of Prematurity Screening database Report number 5. *Arch Dis Child Fetal Neonatal Ed* 2013;98:F327–33.
75. Reynolds JD, Dobson V, Quinn GE, et al. Evidence-based screening criteria for retinopathy of prematurity: natural history data from the CRYO-ROP and LIGHT-ROP studies. *Arch Ophthalmol* 2002;120:1470–6.
76. McCloskey M, Wang H, Jiang Y, et al. Anti-VEGF antibody leads to later atypical intravitreal neovascularization and activation of angiogenic pathways in a rat model of retinopathy of prematurity. *Invest Ophthalmol Vis Sci* 2013;54:2020–6.
77. Martin DF, Maguire MG, Ying GS, et al. Ranibizumab and bevacizumab for neovascular age-related macular degeneration. *N Engl J Med* 2011;364:1897–908.
78. Zehetner C, Kirchmair R, Huber S, et al. Plasma levels of vascular endothelial growth factor before and after intravitreal injection of bevacizumab, ranibizumab and pegaptanib in patients with age-related macular degeneration, and in patients with diabetic macular oedema. *Br J Ophthalmol* 2013;97:454–9.
79. Chemtob S, Hardy P, Abran D, et al. Peroxide-cyclooxygenase interactions in postasphyxial changes in retinal and choroidal hemodynamics. *J Appl Physiol* (1985) 1995;78:2039–46.
80. Neu J, Afzal A, Pan H, et al. The Dipeptide Arg-Gln inhibits retinal neovascularization in the mouse model of oxygen-induced retinopathy. *Invest Ophthalmol Vis Sci* 2006;47:3151–5.
81. Connor KM, SanGiovanni JP, Lofqvist C, et al. Increased dietary intake of omega-3-polyunsaturated fatty acids reduces pathological retinal angiogenesis. *Nat Med* 2007;13:868–73.
82. Hellström A, Smith LE, Dammann O. Retinopathy of prematurity. *Lancet* 2013;382:1445–57.
83. Brown MS, Baron AE, France EK, et al. Association between higher cumulative doses of recombinant erythropoietin and risk for retinopathy of prematurity. *J AAPOS* 2006;10:143–9.
84. Ohls RK, Christensen RD, Kamath-Rayne BD, et al. A randomized, masked, placebo-controlled study of darbepoetin alfa in preterm infants. *Pediatrics* 2013;132:e119–27.